


PERCUTANEOUS SURGICAL CERVICAL DISCECTOMY

Technique and results

D. Gastambide
P.L. Peyrou
(Paris)

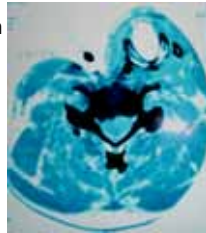
History

T. TAJIMA (Japon)
Brussels 1989
Gastambide: first
cervical discectomy
in France (1990)
French tools (1992)

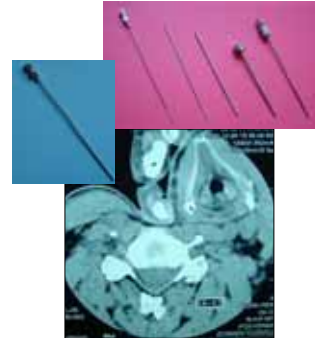


Technique

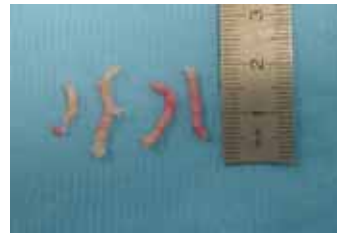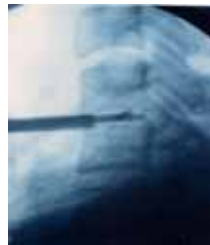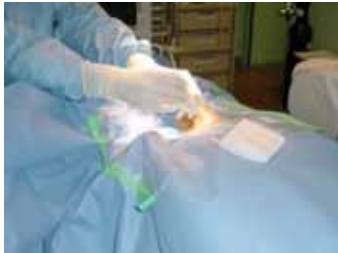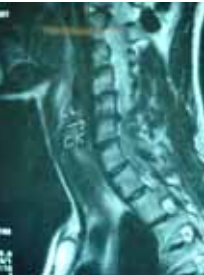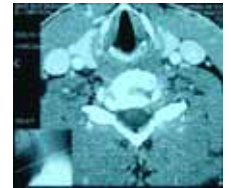right anterolateral approach
under general anesthesia
or
Neuroleptanalgesia and
local anesthesia
C-arm control, lateral and
AP



Guide needle follows operator finger and
penetrates disk anterior rim middle



A special trephine, with an
incorporated auto suction
system, takes of disc cores
until posterior vertebral wall
vertical line



A small disc
forceps takes off
the posterior third
of the disc



Results: 82 patients,

Mean 42 Y

(sex ratio 35/47)

85 operations

57 at 1 level,

most C5C6,

27 at 2 levels ,

**1 at 3 levels during
the same operation.**

Three patients had 2 operations

1 after same level relapse

2 different levels

**Lumbar surgical
operations**

**before (3 months to 3
years): 4 patients**

**after cervical
discectomy (8 days à
3 years): 7 patients**

**Mean follow-up 15
months**

80 known results

57 good (71,2%)

14 fair (17,5%)

88,75% success

9 poor (11,2%) :

**2 arthrodesis in a second
operation**

Complications:

no infection

no neurological complication

no oesophagal nor vascular wound

Discussion:

• *With open surgery, globally 90% satisfied patients. But higher morbidity: complications in 21 patients on 75 at La Pitié 1995-1999 (Journée du rachis de Paris 2001, Sauramps, p.69), 10,5% of complications for S.H. Lee:*

<u>Complications</u>	<u>Perc. Cerv. Discectomy</u>		<u>Open Surgery</u>		
	S.H. LEE	D. GASTAMBIDE	S.H LEE	PITIE Hosp.	J. HACKER
Graft mobilization	0	0	6	4	2
Reversible recurrent nerve impairment	1	0	2	1	1
Graft collapse	/	/	2	10	6
Transitory pyramidal s.	1	0	2	1	0
Cl. Bernard Horner	0	0	1	1	?
Superf. compl. on cerv. Incision or donor site	0	0	1	7	9
Carotid wound	1	0	0	0	0
Sec. sympt. wors.	1	0	0	1	1
Total Complications	4/145 patients	0/82 patients	14/132 patients	25/75 patients	19/142 patients
	4/227 1,76%		58/349 16,61%		

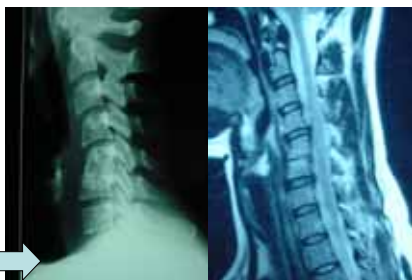• *Chymionucleolysis contra-indications in allergic patients End of Chymiodactine production*

Our indications: *Median, paramedian, lateral hernias, Important hernia size: no contra-indication*

Disco-osteophytic hernias if < osseous part

Border indications:

- Relapsed hernia after open surgery*
- Same level (1 patient)*
- adjacent levels (1 patient)*



Our contra-indications:

- excluded hernias*
- stenosis*
- pyramidal syndromes*
- Severe neurological deficits*

Advantages of perc. Techn.:

- simple, + fast,*
- complications <<:*
 - epidural bleeding=0,*
 - periradicular fibrosis=0,*
 - No graft compl., no post-op kyphosis, no sec. displacement*
- Some indications in disco-osteophytic hernias,*
- No interference with further open surgery*

Disadvantages of perc. T.:

- Learning curve,*
- Specific tools*
- Irradiation,*
- Contra-indication in stenosis*

Conclusion:

Although technical care has to be particularly strict, this method has proved its efficiency and has less complications than open techniques

